



Brigham and Women's Hospital
Founding Member, Mass General Brigham

Bone Health in 2025

Sharon H. Chou, MD

Associate Physician

Division of Endocrinology, Diabetes, & Hypertension

Department of Medicine

Brigham and Women's Hospital

Assistant Professor

Harvard Medical School



Sharon H. Chou, MD



- University of Illinois College of Medicine at Rockford
- Internal Medicine Residency at Beth Israel Deaconess Medical Center in Boston
- Endocrinology Fellowship at University of Chicago
- Assistant Professor, Harvard Medical School
- Associate Physician, Brigham and Women's Hospital
 - Clinical focus: osteoporosis



Disclosures

Shire Pharmaceuticals (not relevant)



Learning Objectives

- Assess fracture risk beyond bone density
- Understand when and how to use non-bisphosphonate osteoporosis treatments



Case 1

Case 1: 62 yo postmenopausal woman

- 62-year-old postmenopausal woman with history of lupus, diagnosed at age 19 years old and treated with glucocorticoids for the first 10 years, and GERD on PPI
 - Gyn history: irregular menses while on glucocorticoids, menopause at 48 years old
 - No history of fracture
 - Screening DXA:

Patient:

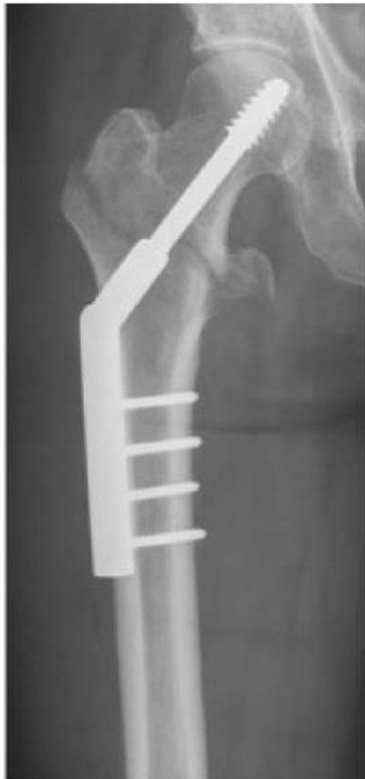- **Major osteoporotic fracture: 13%**
- **Hip fracture: 1.5%**

	T-score	Z-score
L1-L4 spine	-1.6	0.0
L total hip	-1.2	-0.1
L femoral neck	-1.3	0.0



Case 1: 62-year-old postmenopausal woman

- 3 months later, she fell and sustained a R femoral neck fracture.



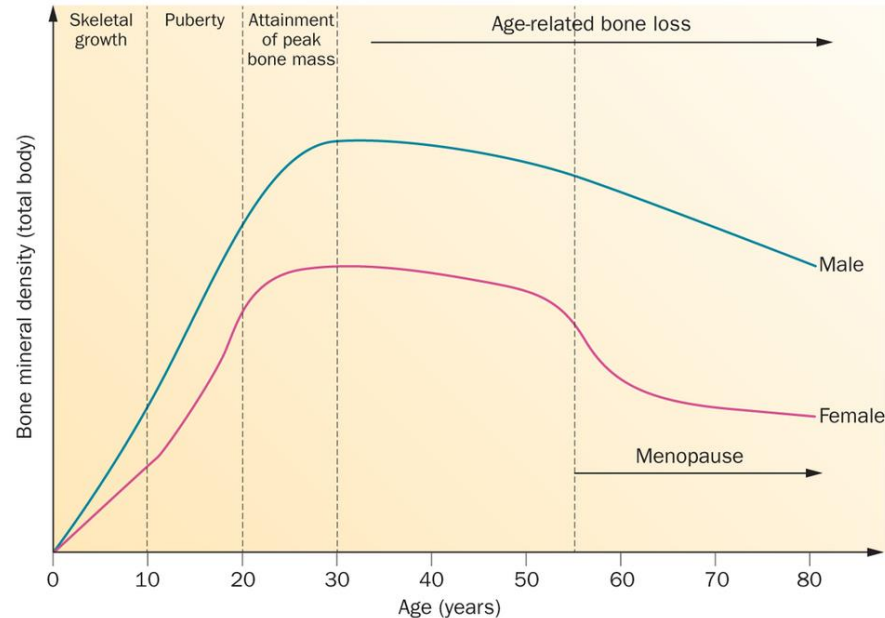
Osteoporosis is defined as a skeletal disorder characterized by *compromised bone strength* predisposing a person to an *increased risk of fracture*



Bone Strength is Determined by Bone Density AND Bone Quality

Bone Density

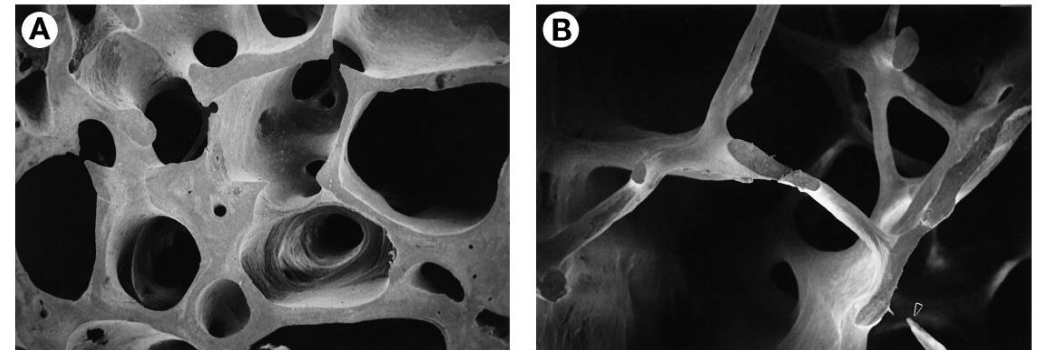
- Peak bone density
- Amount of bone loss



Hendrickx et al. *Nat Rev Rheumatol.* 2015;11(8).

Bone Quality

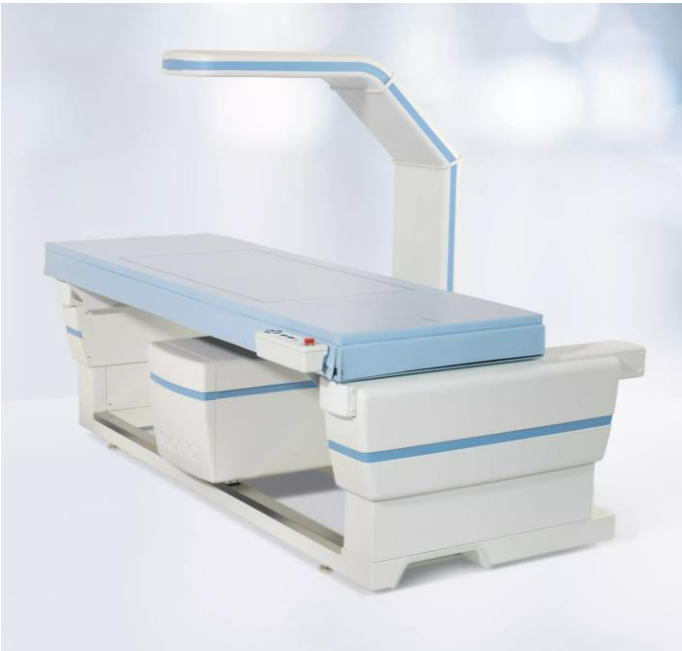- Microarchitecture
- Turnover
- Accumulation of damage
- Mineralization
- Collagen



Dempster. *J Bone Miner Res.* 2000;15(1).
NIH Consensus Development Panel. *JAMA.* 2001;285(6).

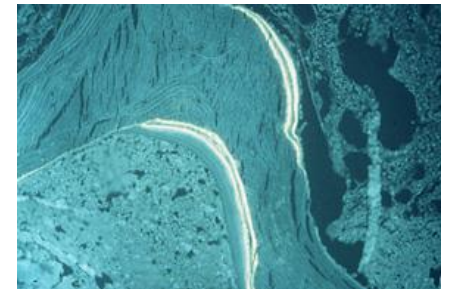
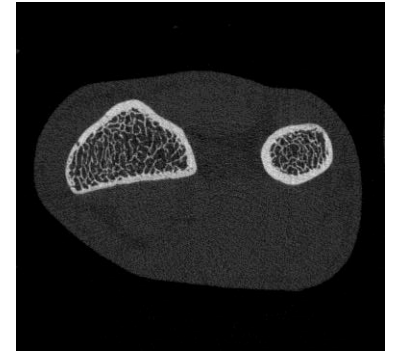
Bone Quality is More Difficult to Measure Clinically

Bone Density



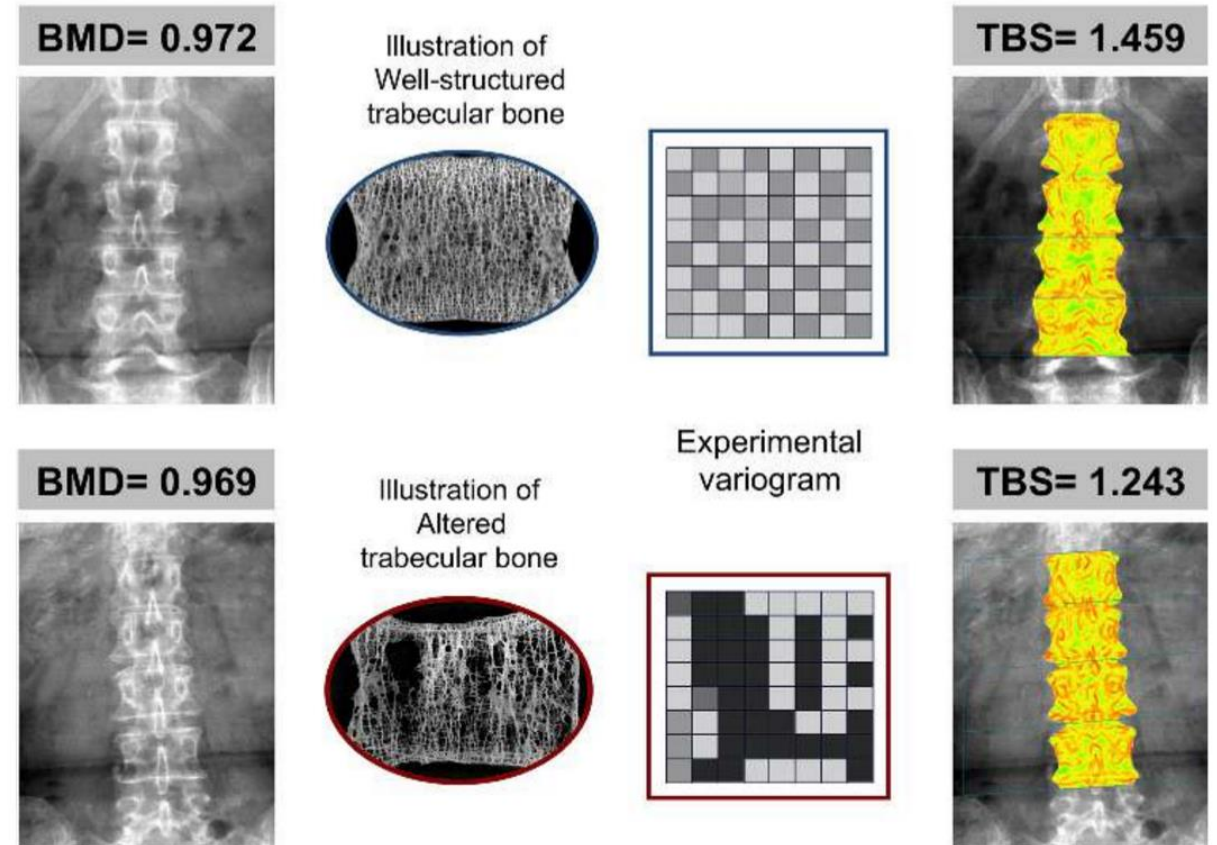
Bone Quality

- Microarchitecture
 - High resolution peripheral quantitative CT (hr-pQCT)
 - Trabecular bone score (TBS)
- Turnover:
 - Bone biopsy with double tetracycline labeling
 - Serum, urine markers
- Accumulation of damage: ?
- Mineralization:
 - Ca, phos, 25OHD, PTH
- Collagen:
 - Genetic testing (osteogenesis imperfecta)



Trabecular Bone Score Estimates Microarchitecture

- Analytical, non-invasive measure of grey-level variation in lumbar spine DXA images to estimate 3D textural characteristics of vertebrae
- Higher TBS associated with better bone *microarchitecture* and lower risk of fractures



Normal	≥1.350
Partially degraded	1.2-1.350
Degraded	≤1.200

TBS predicts fracture risk independent of BMD and FRAX

FRAX® Fracture Risk Assessment Tool

Home Calculation Tool Paper Charts FAQ References

Calculation Tool

Please answer the questions below to calculate the ten year probability of fracture

Country: **US (Caucasian)** Name/ID:

Questionnaire:

1. Age (between 40 and 90 years) or Date of Birth
Age: Date of Birth: Y: M: D:

2. Sex ☐ Male ☒ Female

3. Weight (kg)

4. Height (cm)

5. Previous Fracture ☒ No ☐ Yes

6. Parent Fractured Hip ☒ No ☐ Yes

7. Current Smoking ☒ No ☐ Yes

8. Glucocorticoids ☒ No ☐ Yes

9. Rheumatoid arthritis ☒ No ☐ Yes

10. Secondary osteoporosis ☒ No ☐ Yes

11. Alcohol 3 or more units/day ☒ No ☐ Yes

12. Femoral neck BMD (g/cm²)
Hologic T-score: -2.0

BMI: 26.2
The ten year probability of fracture (%)

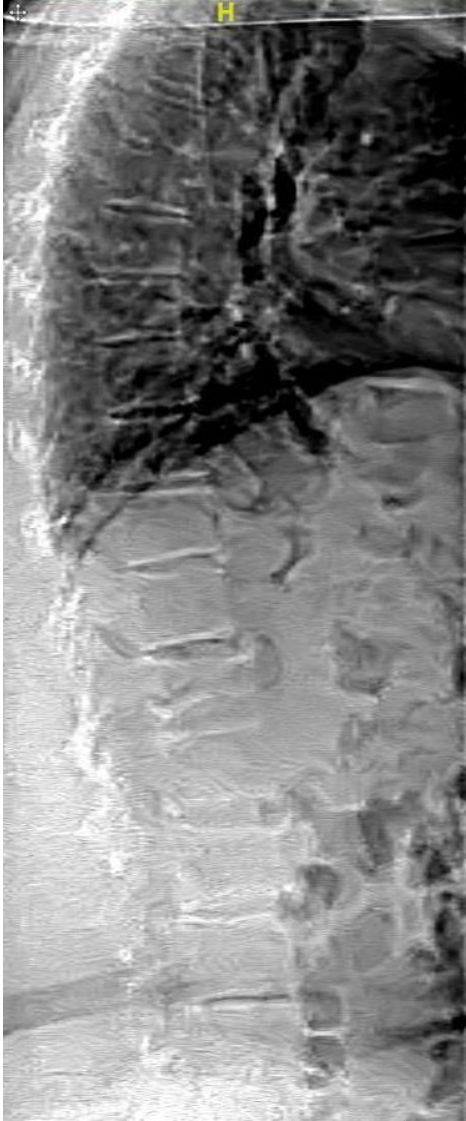
Fracture Type	Probability (%)
Major osteoporotic	11
Hip Fracture	1.6

If you have a TBS value, click here:

Particularly in patients with diabetes and long-term glucocorticoid use



Vertebral Fracture Assessment (VFA)



- Obtained by densitometer
- Importance of vertebral fractures:
 - Associated with increased morbidity and mortality
 - Predict future fractures *independent* of BMD
 - Meets criteria for diagnosis of osteoporosis and indication for treatment

Only 1/3 are clinically diagnosed!



Bliuc et al. *JAMA*. 2009;301(5).
Ross et al. *Ann Intern Med*. 1991;114(11).
Cooper et al. *Bone*. 1993;14 Suppl 1.

Indications for VFA

- T-score <-1.0 AND
 - Women age ≥ 70 years or men age ≥ 80 years
 - Historical height loss >1.5 inches
 - Self-reported but undocumented prior vertebral fracture
 - Glucocorticoid therapy equivalent to ≥ 5 mg of prednisone or equivalent per day for ≥ 3 months



Bone Turnover Markers

- Markers of bone resorption: urinary N-telopeptide (NTX), serum C-telopeptide (CTX)
- Markers of bone formation: serum bone specific alkaline phosphatase, procollagen type 1 N-terminal propeptide (P1NP), osteocalcin
- Epidemiologic studies show high levels predict fracture risk
- Limited clinical usefulness for fracture prediction
 - Large variability (20-70% least significant change)
 - No cut-off to help determine who should be treated



Diagnosis of Osteoporosis

- WHO criteria: BMD at spine, total hip, femoral neck, or 1/3rd radius
- Elevated FRAX:
 - 10-year probability of major osteoporotic fracture $\geq 20\%$
 - 10-year probability of hip fracture $\geq 3\%$
- History of fragility fracture
 - **Hip or spine regardless of BMD**
 - Proximal humerus, pelvis, (wrist) if BMD is in the osteopenia

	T-score criteria
Normal	≥ -1.0
Osteopenia	< -1.0 to > -2.5
Osteoporosis	≤ -2.5



LeBoff et al. *Osteoporos Int.* 2022;33(10).
Camacho et al. *Endocr Pract.* 2020;26(Suppl 1).
Siris et al. *Osteoporos Int.* 2014;25(5).
Wainwright SA et al. *J Clin Endocrinol Metab.* 2005;90.

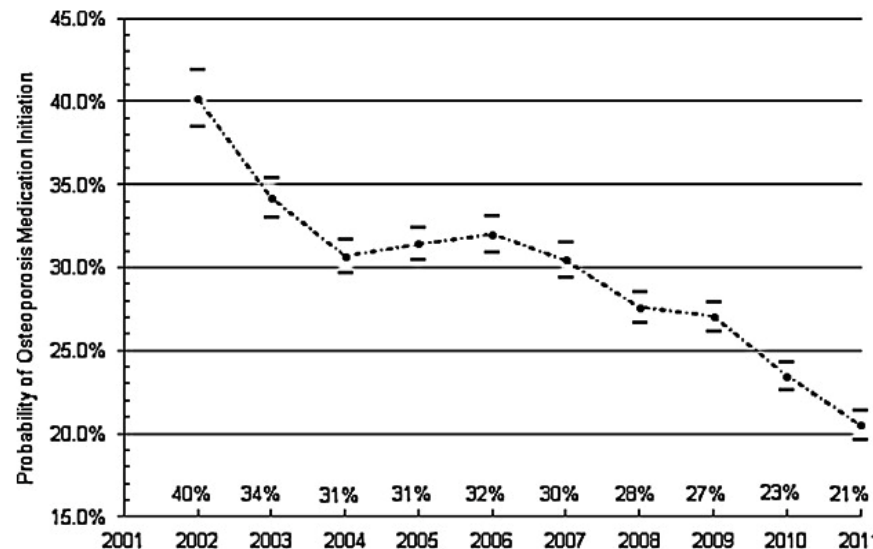
Sustaining a major osteoporotic fracture is highly predictive of having another fracture within 1 year

Subsequent Fracture Rates, within 1 year of Index Fracture

Index fracture

	Overall	Vertebral	Hip
Medicare, n (%)			
Overall (N=45,603)	7,604 (16.7)	1,746 (3.8)	1,256 (2.8)
Vertebral (n=9,465)	1,908 (20.2)	1,235 (13.1)	101 (1.1)
Hip (n=5,024)	1,280 (25.5)	84 (1.7)	719 (14.3)

Yet, only 21% of hip fracture patients were treated for osteoporosis within 12 mo.



Weaver J, et al. *J Manag Care Spec Pharm.* 2017;23(4).
Solomon DH, et al. *J Bone Miner Res.* 2014;29(9).



Case 1: 62-year-old postmenopausal woman

What do you now recommend?

- A) Hormone replacement therapy
- B) Raloxifene
- C) Alendronate
- D) Zoledronic acid
- E) Denosumab



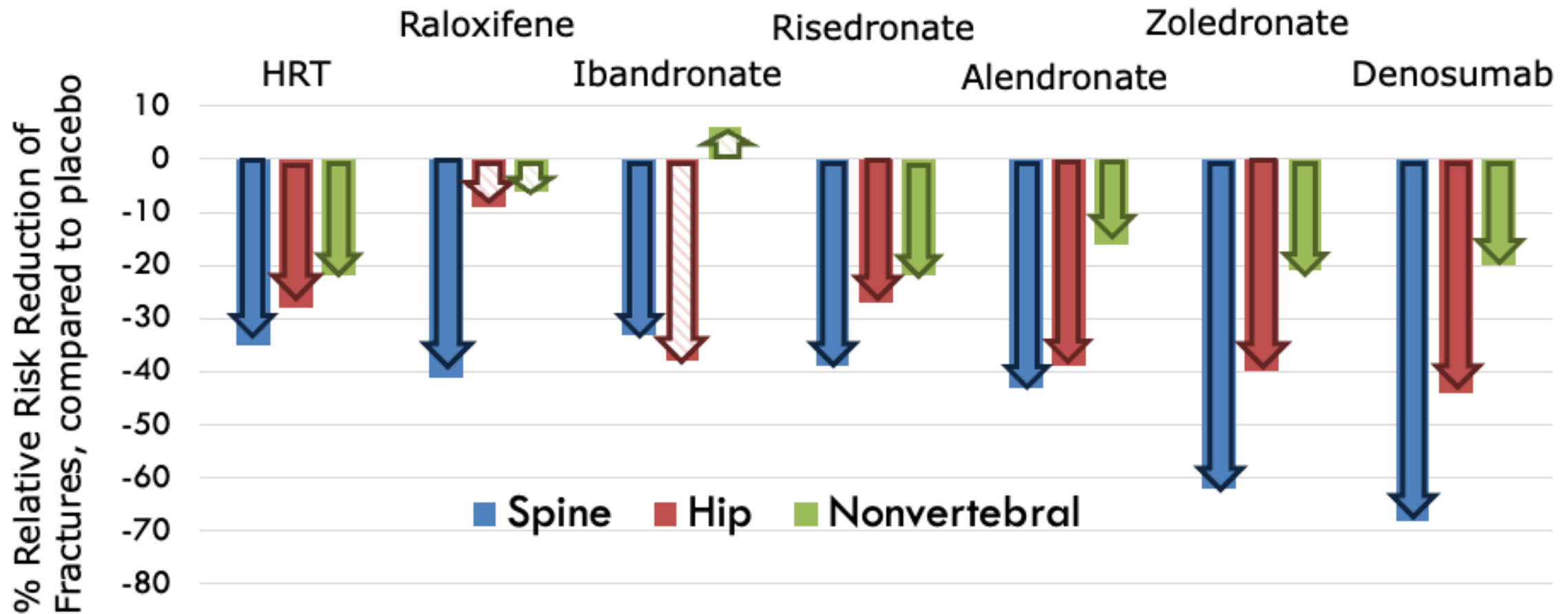
Case 1: 62-year-old postmenopausal woman

What do you now recommend?

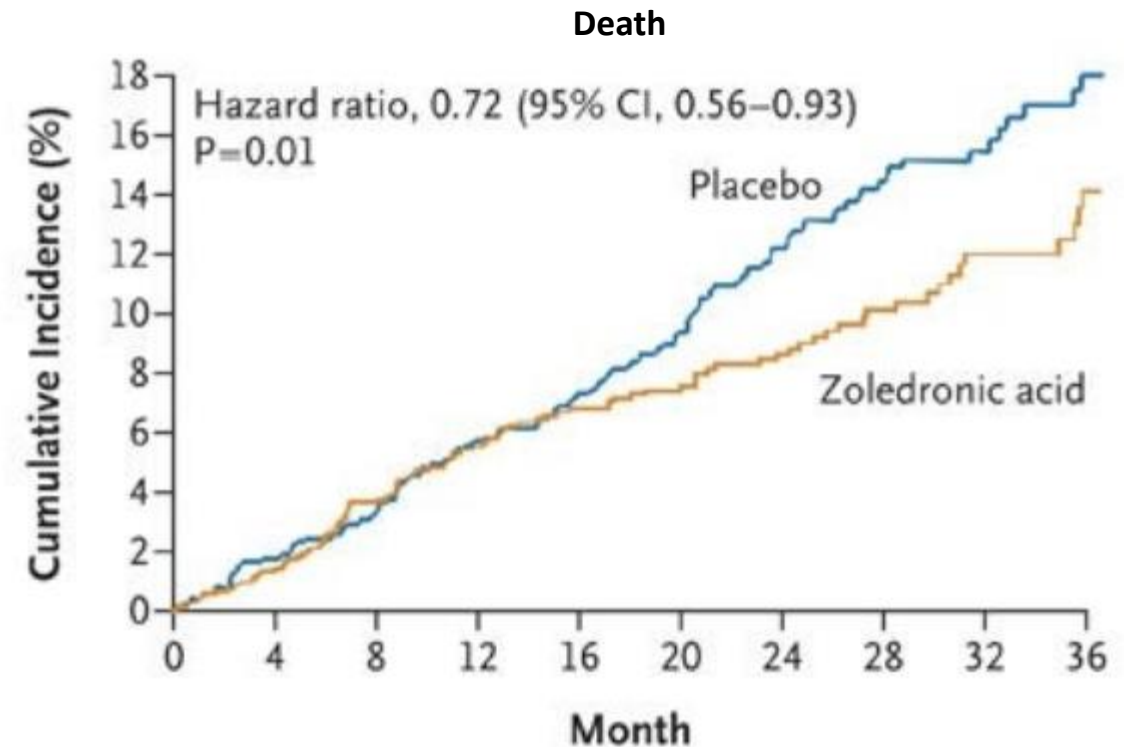
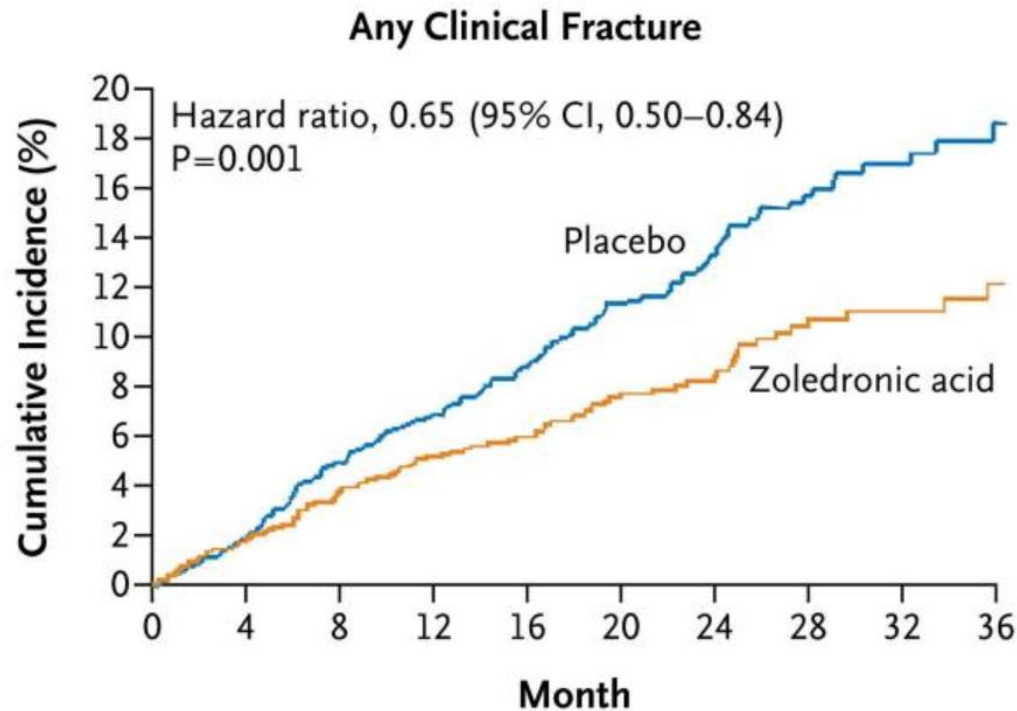
- A) Hormone replacement therapy—>10 years out from menopause
- B) Raloxifene—not potent enough to reduce hip fractures
- C) Alendronate—has a history of GERD
- D) Zoledronic acid**
- E) Denosumab—an option but discontinuation remains a problem



Osteoporosis Medications are Very Effective at Preventing Fractures



Zoledronic acid reduces fractures and mortality post-hip fracture: a randomized controlled trial



Reduced risks of:

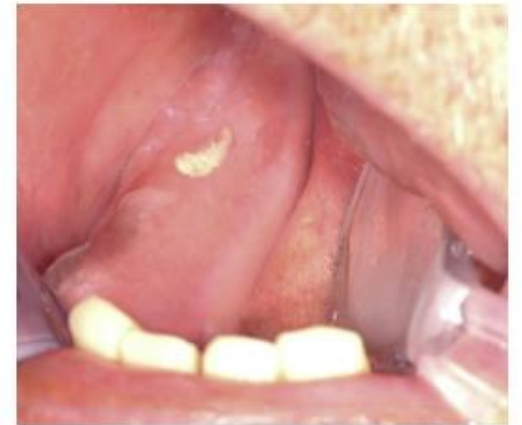- Fractures by 35%
- Vertebral fractures by 46%

Reduces mortality by 28%!



Osteonecrosis of the Jaw is Very Rare

- Presence of exposed bone in the maxillofacial region for >8 weeks
- Multifactorial pathogenesis, including bone remodeling inhibition, inflammation/infection, angiogenesis inhibition, immune dysfunction, genetic predisposition
- Rare in patients treated for osteoporosis:
 - Oral bisphosphonates: $\leq 0.05\%$ (≤ 5 per 10,000)
 - IV bisphosphonates: $\leq 0.02\%$ (≤ 2 per 10,000)
 - Denosumab: 0.04-0.3%
 - Placebo: 0-0.02%
 - Cancer patients: <5%
- Higher risk with invasive procedure (tooth extraction, dental implant)
- Vast majority of cases are mild and treated conservatively



Ruggiero et al. *J Oral Maxillofac Surg.* 2022;80.

Anastasilakis et al. *JCEM.* 2022;107.

Williams et al. *Oral Maxillofac Sug Clin North Am.* 2015;27(4).

Osteonecrosis of the Jaw is Very Rare

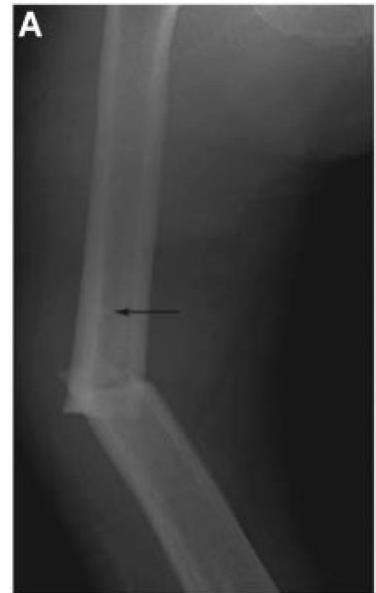American Association of Oral and Maxillofacial Surgeons' Position Paper on ONJ, 2022:

- “Patients are *irrationally* denying themselves the tangible therapeutic benefit of antiresorptive therapy to minimize the risk of fragility fractures in order to prevent a *minuscule* risk of developing MRONJ.”
- Do NOT recommend routine discontinuation of osteoporosis treatment prior to dental procedures
 - Unable to reach a consensus—evenly split between offering drug holidays on a case-by-case recommendations vs never recommending drug holidays



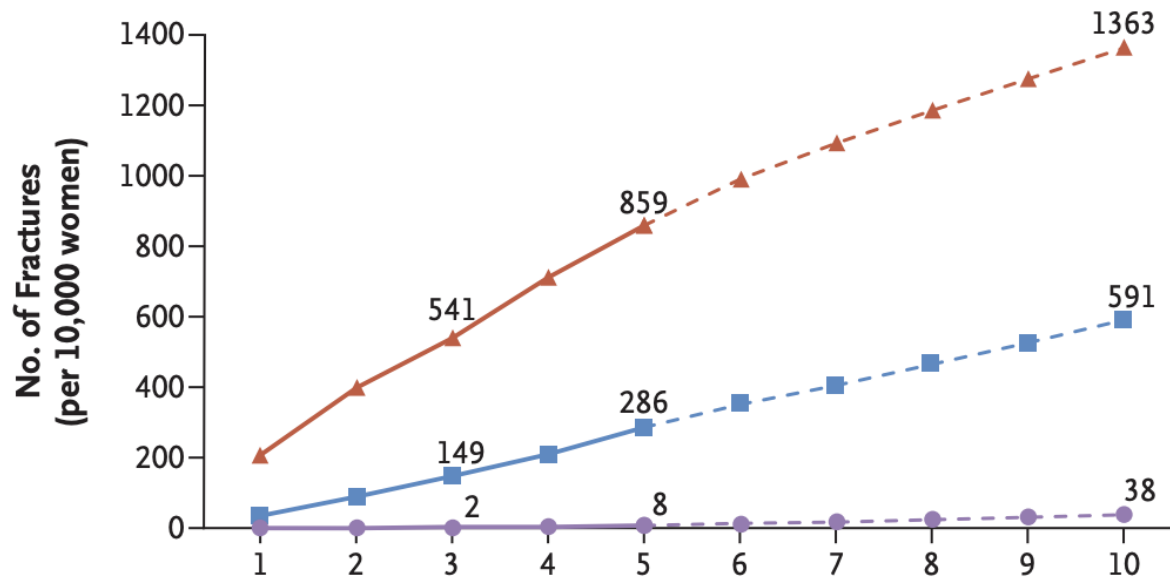
Atypical Femur Fractures are Also Very Rare

- Low-trauma fractures in the subtrochanteric region or femoral shaft
- May begin with stress reaction or stress fracture
 - Anti-resorptive agents may impair the repair process.
- 70% have prodrome of pain in thigh or groin
- 28% with bilateral fractures/radiographic abnormalities
- Absolute risk of 3.2 to 50 cases per 100,000 person-years
 - Decreases 70% per year after stopping BPs

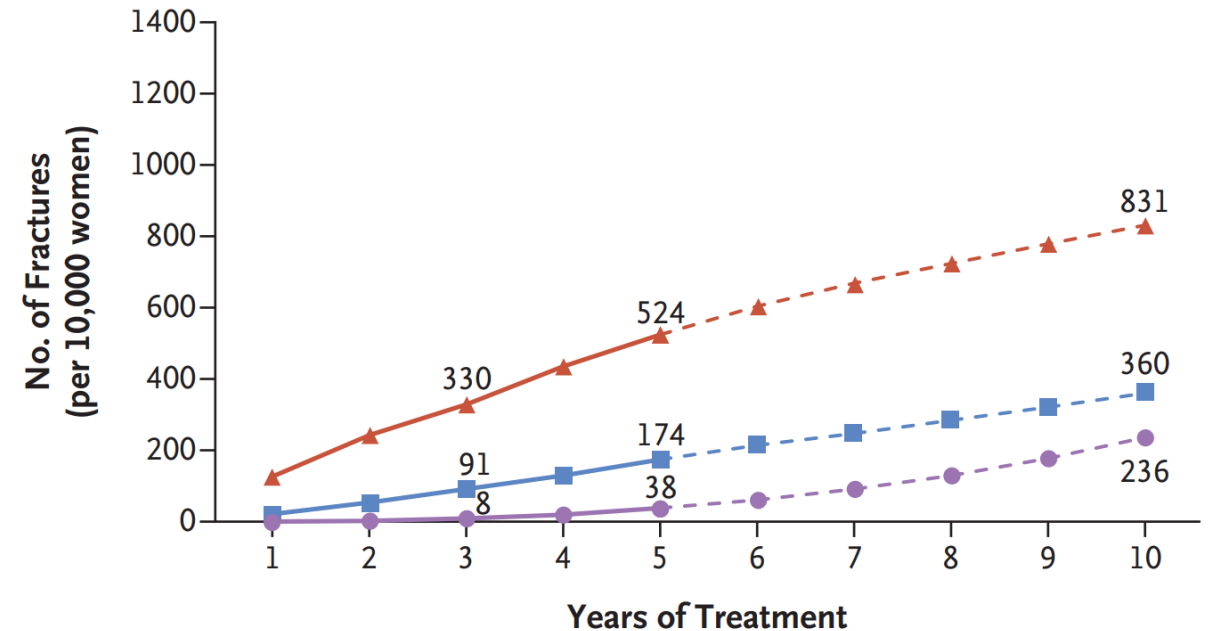


Bisphosphonates prevent many more fractures than cause AFFs, but there are racial differences

B White Women



A Asian Women

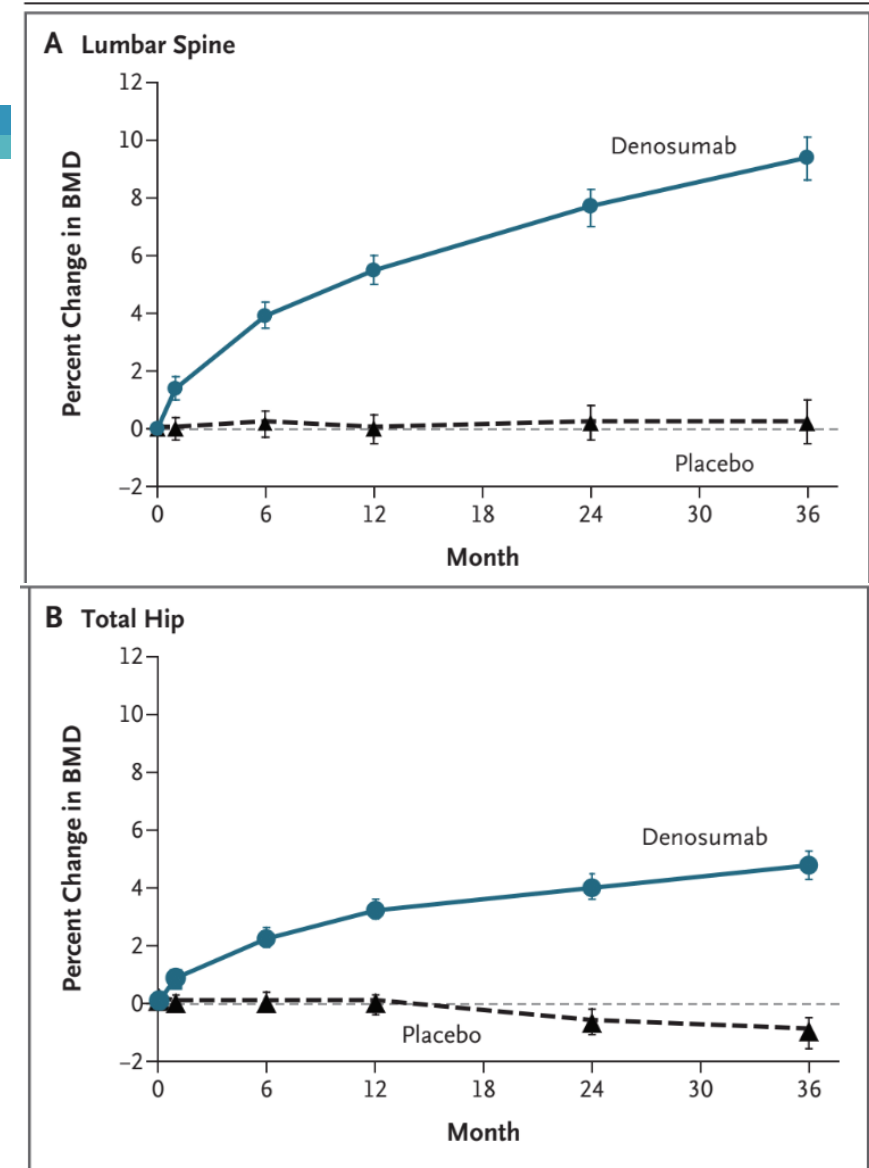


—■— No. of hip fractures prevented —▲— No. of clinical fractures prevented —●— No. of bisphosphonate-associated AFFs



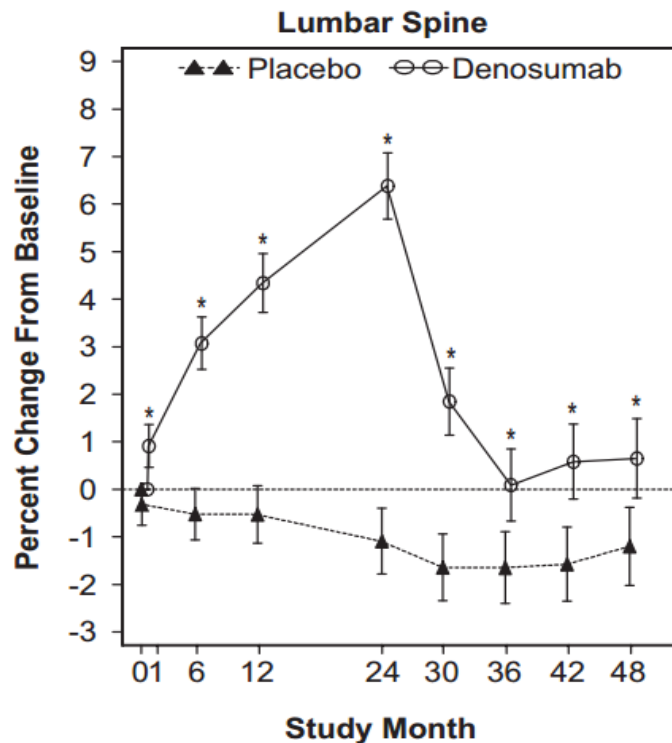
Denosumab

- Antibody that binds and inhibits RANKL, which regulates osteoclastic bone resorption
- Reduces risk of vertebral fractures by 68% and hip fractures by 40% over 3 years
- Okay to use in renal insufficiency
- Adverse events:
 - Hypocalcemia
 - Rashes
 - Cellulitis
 - ONJ, AFF



Denosumab vs. Bisphosphonates

- Similar fracture reduction compared to zoledronate
- Greater, continued increase in BMD
- NO DRUG HOLIDAYS



SHORT REPORT

JBMR®

Clinical Features of 24 Patients With Rebound-Associated Vertebral Fractures After Denosumab Discontinuation: Systematic Review and Additional Cases

Athanasios D Anastasilakis,¹ Stergios A Polyzos,² Polyzois Makras,³ Berengere Aubry-Rozier,⁴ Stella Kaouri,⁵ and Olivier Lamy⁴



Case 1: 62-year-old postmenopausal woman

- Started zoledronic acid 5 mg IV annually
- Repeat DXA, 1 year after 1st dose:

	T-score	Comparison to prior scan
L1-L4 spine	-1.3	+3.4%
L total hip	-1.3	No change
L femoral neck	-1.5	No change

Plan up to 6 years of IV zoledronic acid given history of hip fracture (high risk patient)

- No further fractures



Case 2

Case 2:

- 55-year-old otherwise healthy postmenopausal woman referred for osteoporosis
 - Underwent menopause at age 44

- DXA scan, 1/2014:

	T-score	Z-score
L1-L4 spine	-4.3	-3.2
L total hip	-2.8	-2.1
L femoral neck	-3.1	-2.0

- Lumbar & thoracic spine x-rays: mild compression deformity at T12
- No other history of fracture



Secondary Work-up is Recommended Prior to Osteoporosis Treatment

Basic

- CBC: normal
- Chem: Ca 9.4, phos 4.6, Cr 0.60
- LFTs: alk phos 90, alb 4.0
- 25OHD: 21 ng/mL
- PTH: 74 (12-88)
- 24-hour urine calcium: 140 mg

As clinically indicated

- TSH: 0.73
- TTg IgA: negative
- SPEP/UPEP: negative
- Iron/ferritin
- Homocysteine
- Prolactin
- 24-hour urine free cortisol
- Tryptase: 2
- Urinary histamine
- Bone turnover markers
 - Serum CTX: 933 (104-1008)
 - Urine NTX: 112 (26-124)

Case 2:

Aside from low 25OHD, her secondary work up was unremarkable.
What is the best treatment option?

- A) Raloxifene
- B) Alendronate
- C) Zoledronic acid
- D) Denosumab
- E) Teriparatide/Abaloparatide



Case 2:

Aside from low 25OHD, her secondary work up was unremarkable.
What is the best treatment option?

- A) Raloxifene
- B) Alendronate
- C) Zoledronic acid
- D) Denosumab
- E) Teriparatide/Abaloparatide—starting with an anabolic agent first will maximize gains in BMD and teriparatide has been shown to be more effective than risedronate in reducing fractures in women with history of vertebral fractures

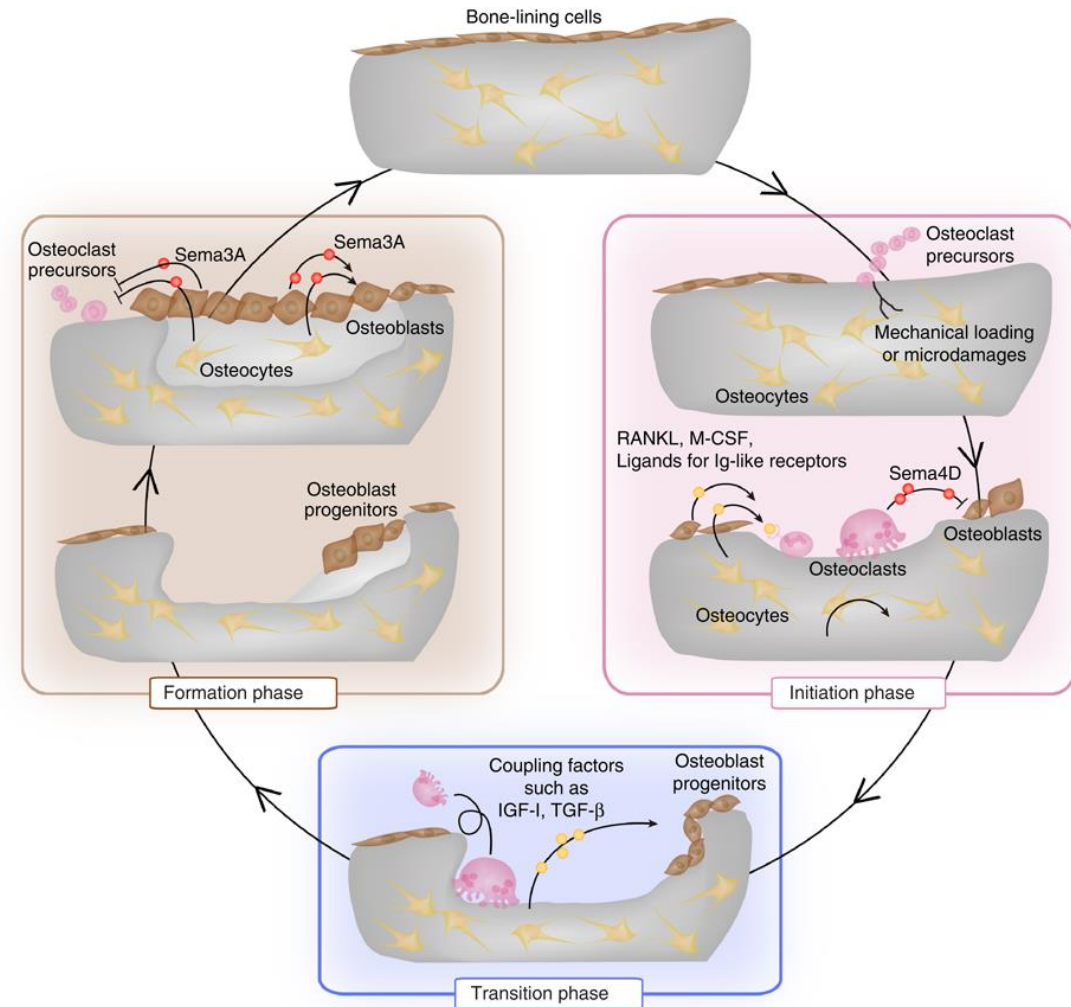


Categories of Pharmacologic Treatment

Antiresorptive therapies
block osteoclastic bone
resorption.

Anabolic therapies
promote osteoblastic bone
formation.

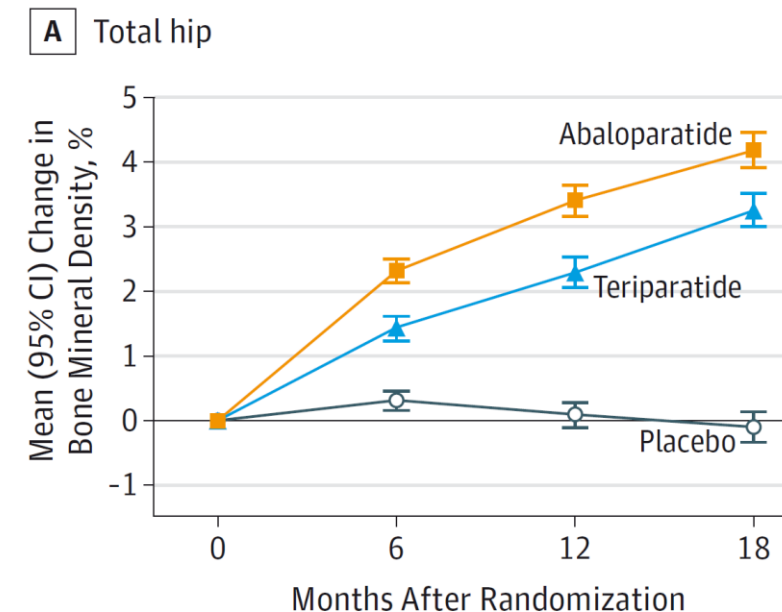
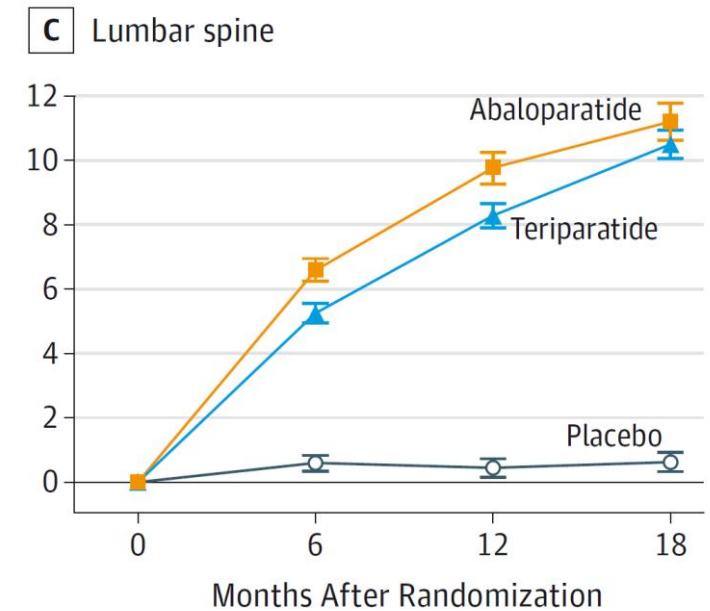
Dual action



Anabolic Agents: parathyroid hormone-based therapies

- Teriparatide (PTH) vs. Abaloparatide (PTHrP)
- Daily subcutaneous injections

	Abaloparatide vs. placebo	Teriparatide vs. placebo	Abaloparatide vs. teriparatide
Vertebral fracture	0.14 (0.05-0.39)	0.20 (0.08-0.47)	
Nonvertebral fracture	0.57 (0.32-1.00)	0.72 (0.42-1.22)	0.79 (0.43-1.45)
Major osteoporotic fracture	0.30 (0.15-0.61)	0.67 (0.39-1.14)	0.45 (0.21-0.95)



Parathyroid hormone-based therapies

- Prior black box warning: osteosarcoma noted in rats
 - *2-year lifetime limit removed from teriparatide!*
 - Still avoid in patients with Paget's disease, bone metastases or history of skeletal malignancies, prior radiation therapy involving the bone
- Other precautions: hypercalcemia, primary hyperparathyroidism, nephrolithiasis, hypercalciuria
- Adverse effects: dizziness, palpitations, headaches, nausea, and leg cramps



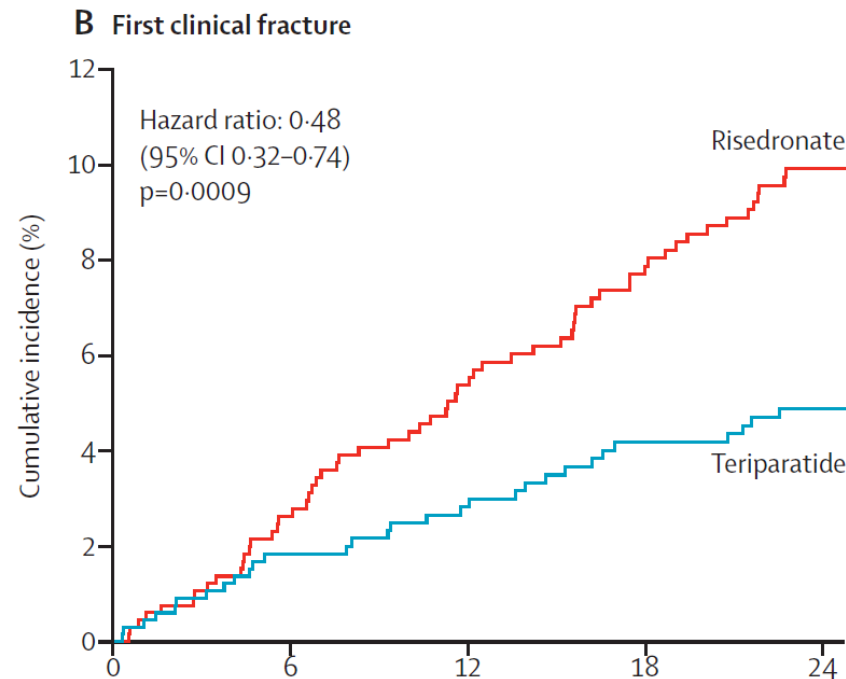
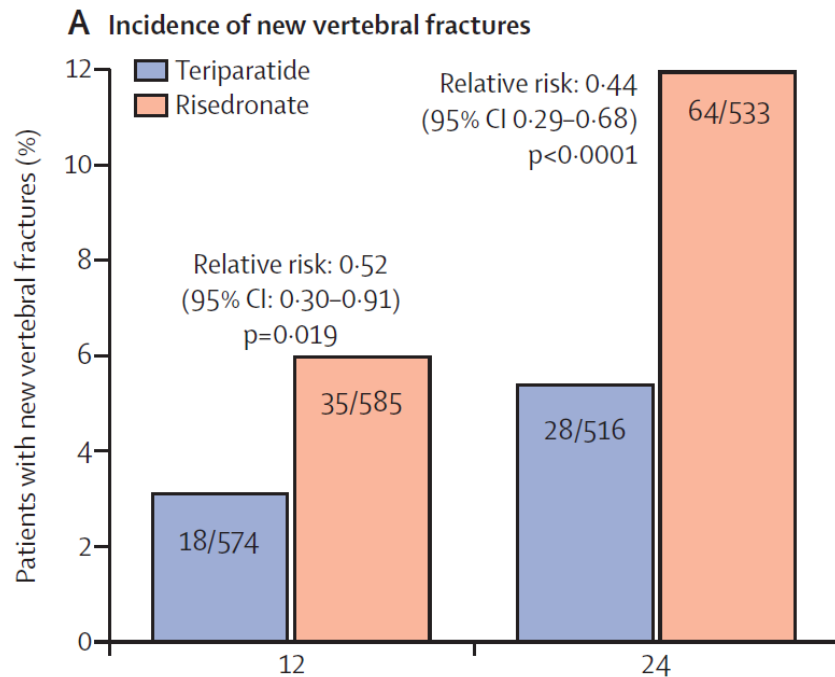
Sequence Matters

Use anabolic agents PRIOR to anti-resorptive agents
to get the most gains in BMD

Treatment paradigm	% Change in total hip BMD during TPTD/PTH treatment			
	6 mo	12 mo	18 mo	24 mo
Alendronate (mean 29.3 mo) → TPTD (18 mo)	−1.8%	−1.0%	+0.3%	−
Alendronate (median 29.2 mo) → TPTD (24 mo)	−1.2%	−0.6%	+0.6%	+2.1%
Risedronate (median 23.4 mo) → TPTD (24 mo)	−1.6%	−0.4%	+0.9%	+2.9%
Risedronate (mean 37.2 mo) → TPTD (12 mo)	−1.2%	−0.3%	−	−
Alendronate (mean 38.0 mo) → TPTD (12 mo)	−1.9%	−1.7%	−	−
Alendronate (mean 45.7 mo) → TPTD (18 mo)	−0.8%	−	+0.9%	−
Teriparatide (treatment naïve)		+2%	+3%	



PTH-based Therapies are More Effective than Oral Bisphosphonates in Patients with Vertebral Fractures



Teriparatide vs. risedronate for 2 years in 1,360 postmenopausal women with history of vertebral fracture(s)



Case 2:

- Took teriparatide between 2014-2016
- DXA scan, 7/2016 (age 58):

	T-score	Comparison to 1/2014
L1-L4 spine	-3.0	24.7% increase
L total hip	-2.6	4.2% increase (nonsig)
L femoral neck	-3.0	

- Recommended denosumab but did not follow through



Case 2:

- DXA scan, 4/2019 (age 60):

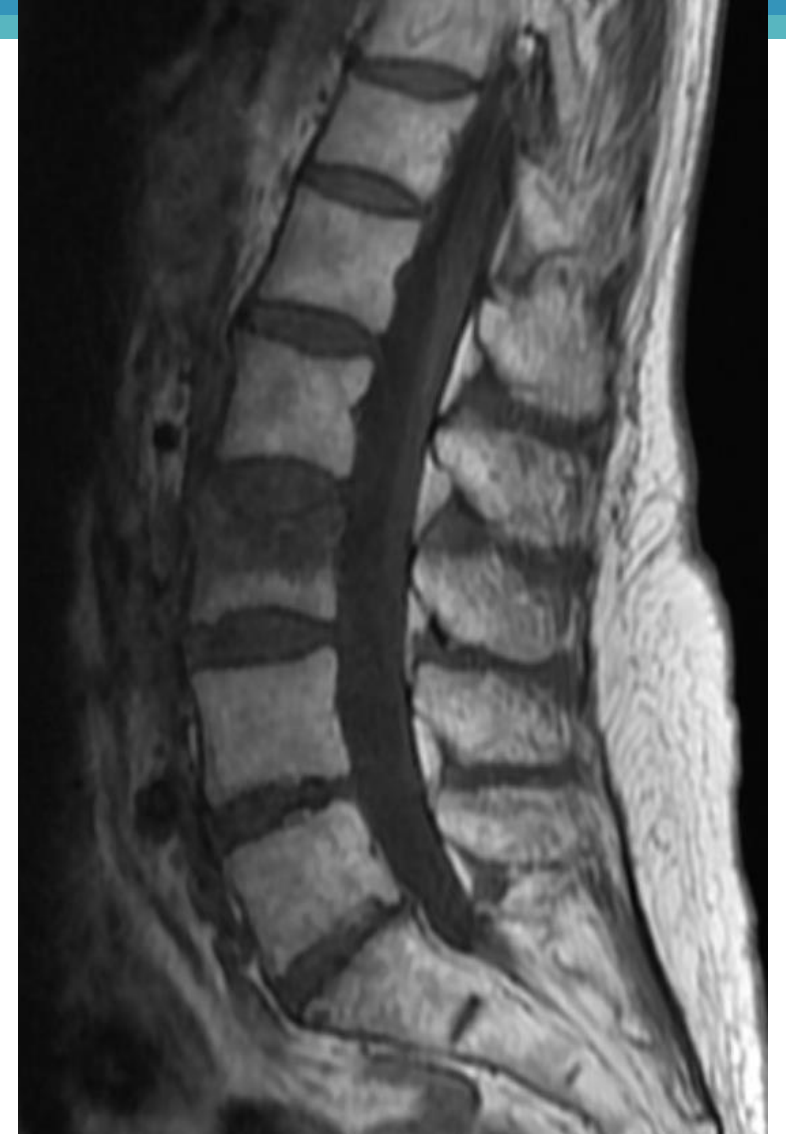	T-score	Z-score	7/2016 T-score (different facility)
L3-L4 spine (L1-L4 spine)	-5.3 (-4.1)	-3.8	-3.0
L total hip	-3.2	-2.2	-2.6
L femoral neck	-3.0	-1.0	-3.0

Anabolic therapy needs to be followed by antiresorptive therapy to maintain BMD gains!



Case 2:

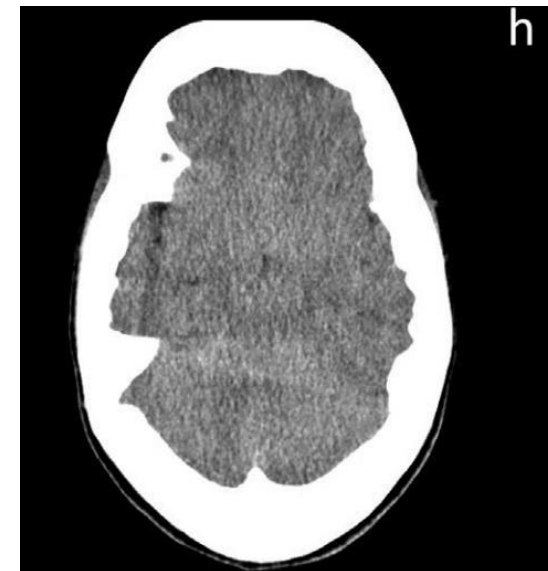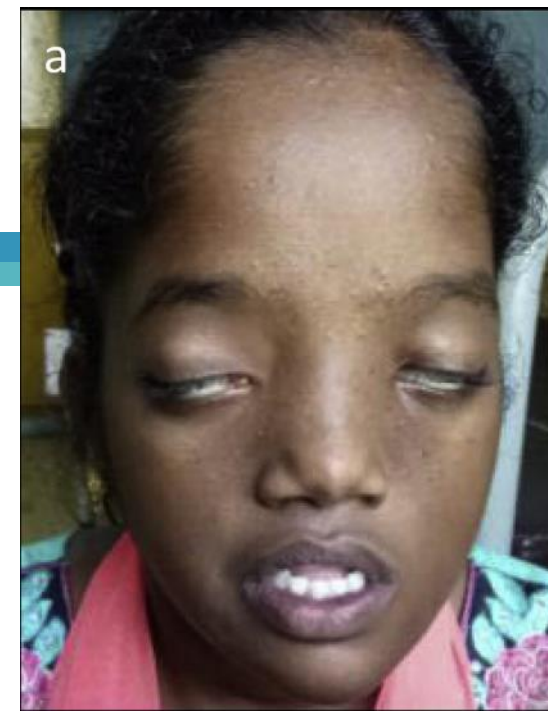- 2/2020: L3 compression fracture from slipping off a seat on the boat (didn't actually hit the deck)



The NEW Anabolic Agent (technically dual agent): Romosozumab

- FDA approved in 2019
- Monthly subcutaneous injection for 12 months
- Based on the disease sclerosteosis, a rare genetic disorder with high bone mass due to loss-of-function mutation in SOST
- Sclerostin is produced by osteocytes, inhibits bone formation and enhances bone resorption
- Monoclonal antibody that binds and inhibits sclerostin

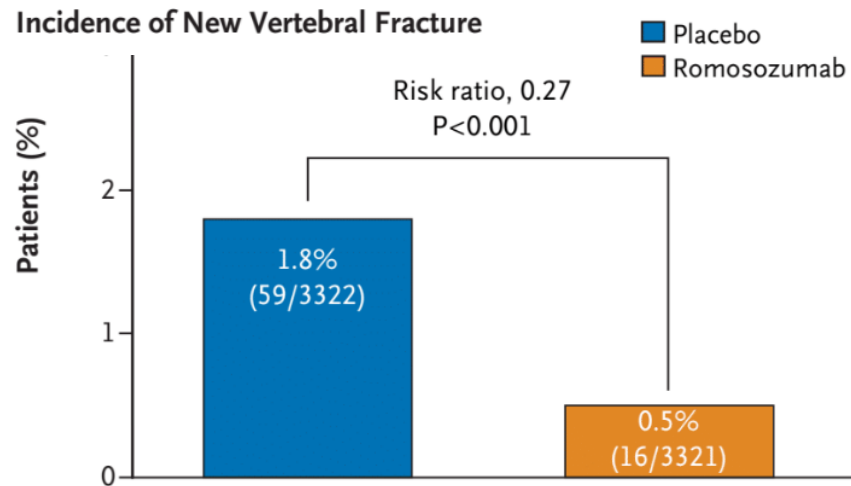
Romosozumab increases bone formation and bone resorption *at the same time*



Romosozumab Reduces Fractures Effectively

FRAME

Vs. placebo for 12 mo, followed by denosumab for 12 mo

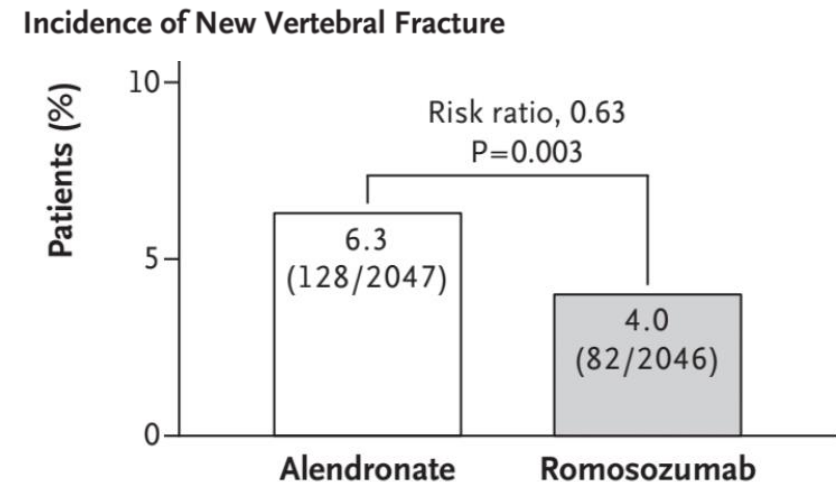


36% reduction in clinical fractures
(1.6 v. 2.5%)

Cosman et al. *N Engl J Med*. 2016;375(16).

ARCH

Vs. alendronate for 12 mo, followed by alendronate



19% reduction in nonvertebral fractures,
38% in hip fractures

Saag et al. *N Engl J Med*. 2017;377(15).



Romosozumab May Increase Cardiovascular Risk

- Injection site reaction, mostly mild: 5.2% v. 2.9%
- Few cases of ONJ and AFF
- More adjudicated serious cardiovascular events with romosozumab (2.5%) than with alendronate (1.9%; OR 1.31 [0.85-2.00])
 - Not seen against placebo

Should not be initiated in patients who have had a myocardial infarction or stroke within the preceding year.



Case 2:

- Started romosozumab, finished 12 injections in 9/2021
- DXA scan, 10/2021 (age 63):

	T-score	Comparison to 4/2019
L1-L4 spine	-4.2	25.0% increase
L total hip	-2.9	7.5% increase (nonsig)
L femoral neck	-2.6	

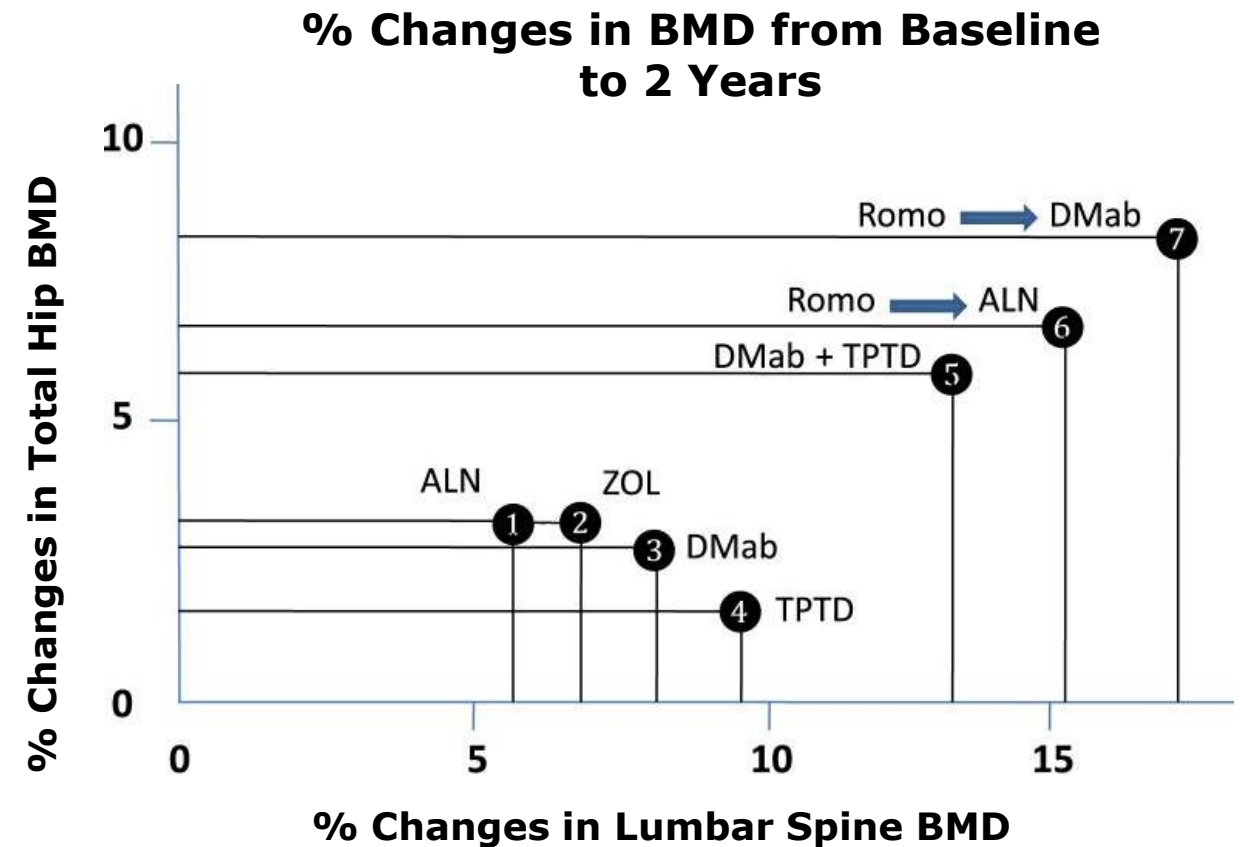
- No new fractures

What now?



Case 2:

- Sequence Matters (cont.):
all anabolic therapies need
to be followed by
antiresorptive agents
- Transitioned to denosumab



Case 2:

- Transitioned to denosumab in 11/2021
- DXA scan, 1/2023 (age 64):

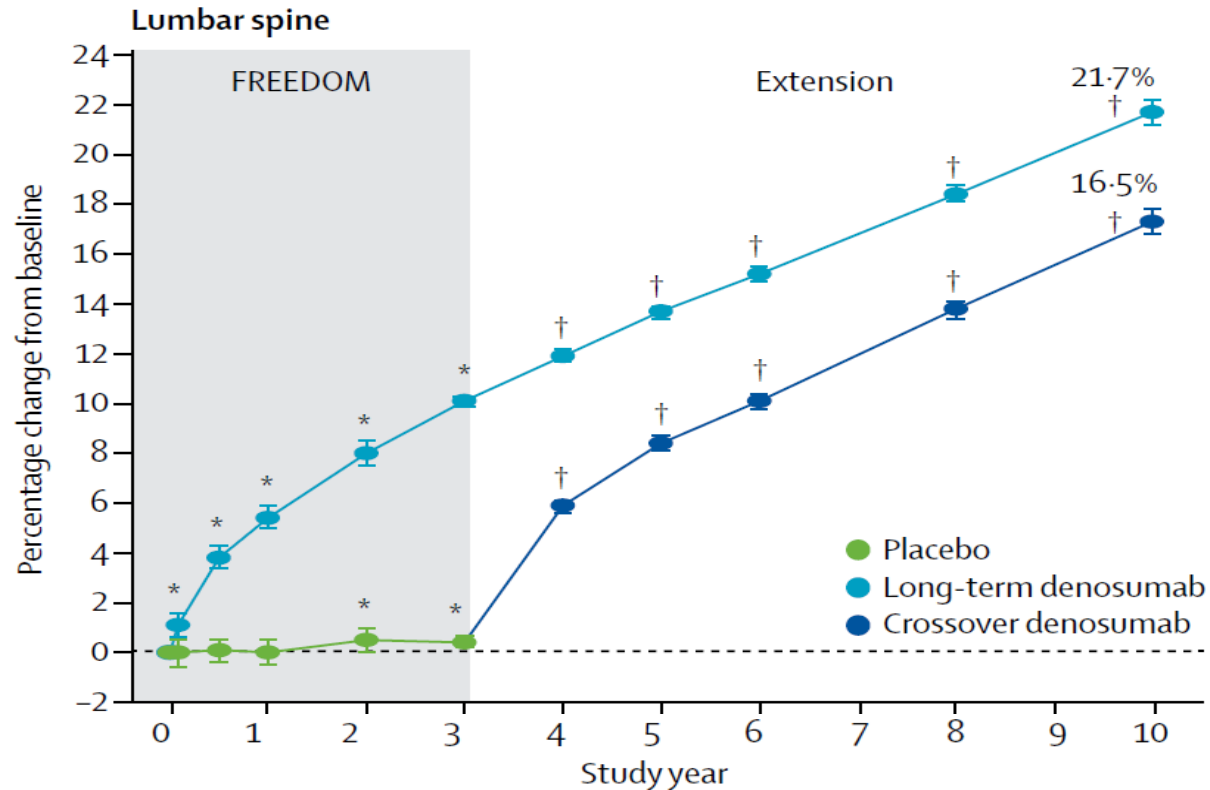
	T-score	Comparison to 10/2021
L1-L4 spine	-3.4	13.4% increase
L total hip	-2.6	5.1% increase
L femoral neck	-2.3	

- No new fractures

How long can she be on denosumab?



Denosumab is Efficacious and Safe out to 10 Years



- Stable incidence of all adverse events
 - 2 cases of AFF (out of 4,074)
 - 12 cases of ONJ
 - 0.7% in women reporting an invasive oral procedure/event
 - 0.05% in women without

Fracture risk continues to decline as well.

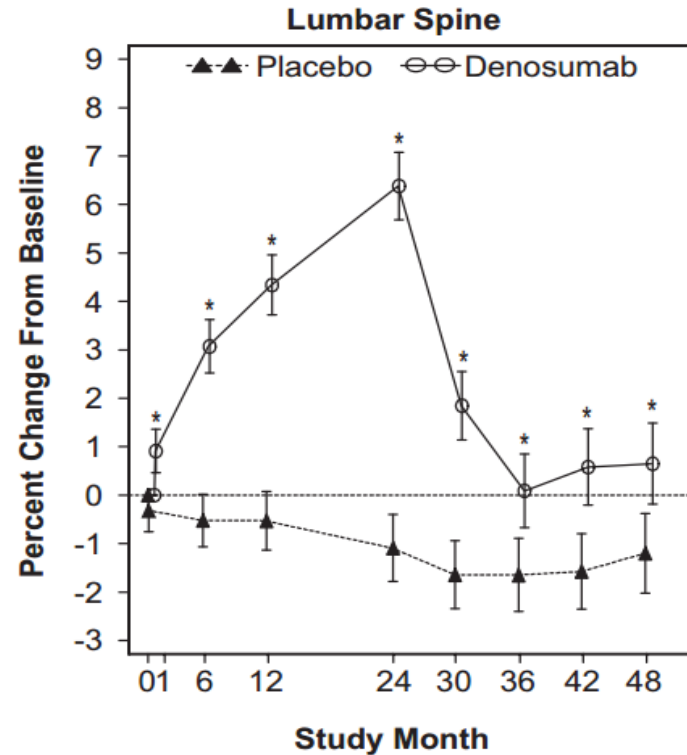


Bone et al. *Lancet Diabetes Endocrinol.* 2017;5(7).

Ferrari et al. *J Clin Endocrinol Metab.* 2019;104.

Watts et al. ASBMR Annual Meeting. 2017, abstract 1016.

Denosumab Discontinuation Results in Rebound Bone Loss and May Increase Vertebral Fracture Risk



SHORT REPORT

JBMR®

Clinical Features of 24 Patients With Rebound-Associated Vertebral Fractures After Denosumab Discontinuation: Systematic Review and Additional Cases

Athanasios D Anastasilakis,¹ Stergios A Polyzos,² Polyzois Makras,³ Berengere Aubry-Rozier,⁴ Stella Kaouri,⁵ and Olivier Lamy⁴

Higher risk of multiple vertebral fractures, particularly in patients with history of *prior vertebral fracture* (3.9x).

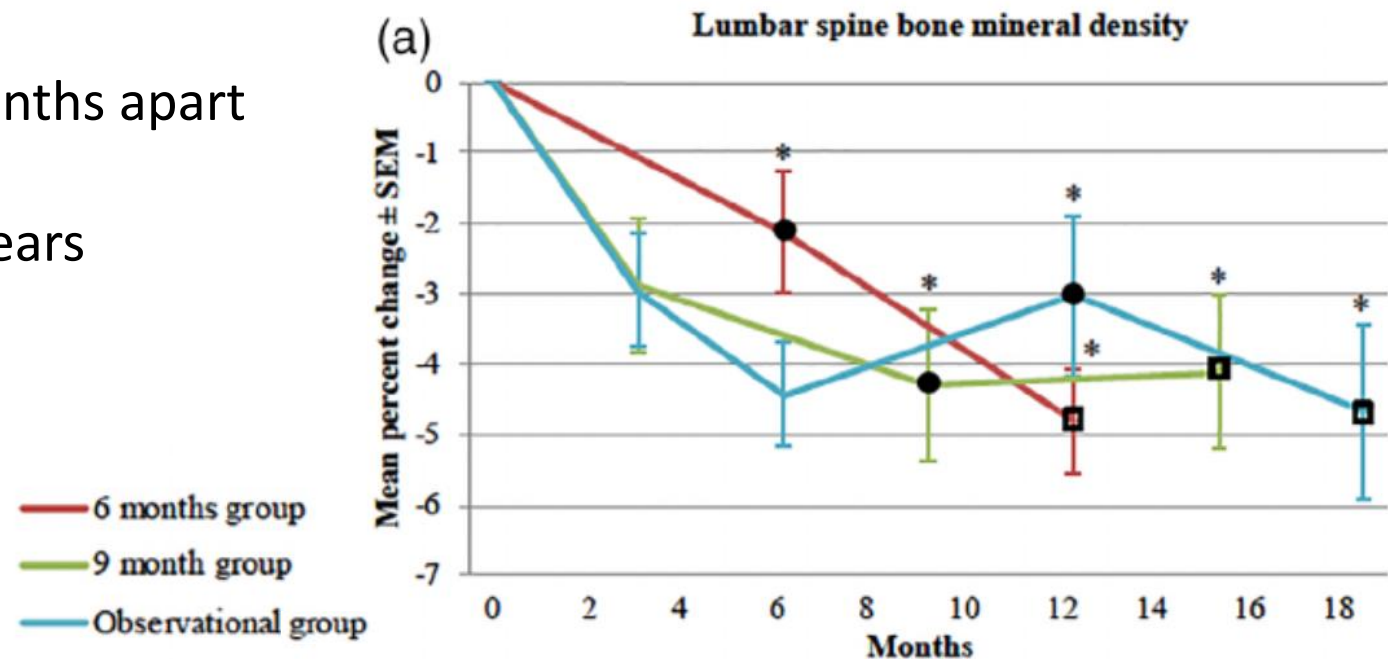
Brown et al. *J Bone Miner Res.* 2013;28(4).

Cummings et al. *J Bone Miner Res.* 2018;33(2).

Bone et al. *J Clin Endocrinol Metab.* 2011;96(4).

How Can Denosumab be Safely Discontinued? (Can it be?)

- 2020 European Calcified Tissues Society position statement:
 - Short-term use of denosumab (≤ 2.5 years): oral/IV bisphosphonate for 1-2 years with monitoring of bone turnover markers (BTMs)
 - Long-term use of denosumab: zoledronic acid 6 months after last dose of denosumab, monitor BTMs after 3 and 6 months, and repeat zoledronic acid if BTMs persistently increase
 - 2 doses of zoledronic acid 6 months apart if unable to measure BTMs
 - Oral bisphosphonates for 1-2 years



Case 2:

- She has significant fracture history, BMD still low (T-score -3.4), so will continue denosumab for now.
- For other young patients, denosumab to bisphosphonate transition seems to more successful if the duration of denosumab use is limited to 1-2 years
- For older patients at high risk of fracture, I usually keep on denosumab indefinitely



When to Use Anabolic Agents

- Recommended for patients with very high risk of fracture
 - Very low bone density, esp. at the spine (before antiresorptive therapy)
 - History of fragility fracture, esp. vertebral fracture (VERO trial)
 - Failed other osteoporosis therapies
 - Prolonged antiresorptive therapy (no ONJ, AFF)



How to Choose Therapy

- For most patients, consider bisphosphonates (oral or IV) or denosumab
 - Ibandronate or raloxifene for patients with only spinal concerns
- For *very* high-risk patients, consider PTH analogs, romosozumab, denosumab, and zoledronate:
 - Recent fracture (within past 12 months)
 - Fracture while on osteoporosis therapy
 - Multiple fractures
 - Fractures while on drugs with skeletal harm (eg glucocorticoids)
 - Very low T-score (<-3.0)
 - High risk of falls or history of injurious falls
 - Very high FRAX ($>30\%$, $>4.5\%$)



Key Points

- A major osteoporotic fracture (spine, hip) should trigger osteoporosis treatment, regardless of BMD results.
- The benefits of osteoporosis treatments far outweigh the risks of ONJ and AFF.
- Denosumab should not be stopped without being followed by a different medication for osteoporosis.
- Consider anabolic agents in patients with very low bone density (prior to anti-resorptive treatments) or history of vertebral fractures.



References

- American College of Physicians: Pharmacologic Treatment of Primary Osteoporosis or Low Bone Mass to Prevent Fractures in Adults. *Ann Intern Med.* 2023;176(2).
- Bone Health & Osteoporosis Foundation: The Clinician's Guide to Prevention and Treatment of Osteoporosis. *Osteoporos Int.* 2022;33(10).
- AACE Clinical Practice Guidelines for the Diagnosis and Treatment of Postmenopausal Osteoporosis. *Endocr Pract.* 2020;26(Suppl 1).
- Endocrine Society: Pharmacological Management of Osteoporosis in Postmenopausal Women. *J Clin Endocrinol Metab.* 2020;105(3).
- Endocrine Society: Osteoporosis in Men. *J Clin Endocrinol Metab.* 2012;97(6).
- Managing Osteoporosis in Patients on Long-Term Bisphosphonate Treatment: Report of a Task Force of the American Society for Bone and Mineral Research. *J Bone Miner Res.* 2016;31(1).

